The Spine Journal 14 (2014) e1–e3

Case Report

Reduction of caudal traction force using dural sac opening rather than spinal cord detethering for tethered cord syndrome caused by lipomyelomeningocele: a case report

Yasuaki Murata, MD, PhD*, Kohichi Kanaya, MD, PhD, Hiroyoshi Wada, MD, PhD, Keiji Wada, MD, PhD, Masahiro Shiba, MD, Yoshiharu Kato, MD, PhD

Department of Orthopaedic Surgery, Tokyo Women's Medical University, 8-1 Kawadacho, Shinjuku, Tokyo, Japan

Received 13 October 2013; accepted 27 February 2014

Abstract

BACKGROUND CONTEXT: A few reports have addressed tethered cord syndrome. Detethering surgery has been performed in these cases because abnormal tension on the spinal cord causes neurologic and urologic symptoms.

PURPOSE: To discuss the surgical treatment of tethered cord syndrome with the belief that the tension on the cord can be decreased by shifting tethered cord to the dorsal side.

STUDY DESIGN: A patient with tethered cord syndrome was surgically treated by shifting the tethered cord to the dorsal side by harnessing the lumbar lordosis instead of detethering.

METHODS: We performed surgery to shift the tethered cord to the dorsal side by harnessing the lumbar lordosis to decrease the tension on the spinal cord.

RESULTS: The tethered cord that was pressed to the ventral side because of a lipoma was shifted dorsally by laminectomy and opening of the dural sac. Pain and numbness were alleviated immediately after surgery.

CONCLUSIONS: The method used in the present case, that is, shifting the tethered cord and lipoma to the dorsal side by harnessing the lumbar lordosis instead of detethering, is a viable treatment option for tethered cord syndrome.

Keywords: Tethered cord syndrome; Lipomyelomeningocele; Lumbar lordosis; Laminectomy; Dural sac opening; Detethering

Introduction

Although a few reports have addressed tethered cord syndrome, almost all of the cases were treated surgically by detethering [1–9]. Instead of detethering, we performed surgery to reduce the caudal traction force of the tethered cord by opening the lamina and dural sac and shifting the tethered cord to the dorsal side by harnessing the lumbar lordosis. Hence, we report the case of a 58-year-old woman who suffered from pain and numbness in the posterior lower limbs and soles that was caused by a tethered cord in a lipomyelomeningocele. The patient underwent surgical shifting of the cord to the dorsal side. With the belief that shifting of the tethered cord to a bowstring orbit could be a viable surgical treatment option for tethered cord syndrome, we discuss the clinical features of this case.

Case report

In April 2009, a 58-year-old woman presented at our hospital with pain and numbness in the posterior side of her lower limbs and soles and urinary dysfunction that had begun 40 years before presentation. She became conscious of worsening pain and numbness without a trigger 2 years before presentation. Although she was treated at other hospitals, including urology departments, before our own, her pain, numbness, and urinary dysfunction had not shown improvement. She experienced bilateral pain and numbness in the buttocks, calves, and soles. Neurologic examination showed both hypalgesia and paresthesia in both sides of S1 and below

FDA device/drug status: Not applicable.

Author disclosures: ***YM:*** Nothing to disclose. ***KK:*** Nothing to disclose. ***HW:*** Nothing to disclose. ***KW:*** Nothing to disclose. ***MS:*** Nothing to disclose. ***YK:*** Nothing to disclose.

* Corresponding author. Department of Orthopaedic Surgery, Tokyo Women's Medical University, 8-1 Kawadacho, Shinjuku, Tokyo 162-8666, Japan. Tel.: (81) 3-3353-8111; fax: (81) 3-3354-7360.

E-mail address: yasuakimurata@ort.twmu.ac.jp (Y. Murata)

1529-9430/$ - see front matter
http://dx.doi.org/10.1016/j.spinee.2014.02.031

Fig. 1. Magnetic resonance imaging of the lumbar spine. (Left) Sagittal plane, T2-weighted sequence before surgery. The image shows the tethered cord and lipomyelomeningocele. Lipoma occupied the spinal canal space at the level of the L4 vertebra and below. The tethered cord was shifted to the ventral side by the lipoma (arrow). (Middle) Sagittal plane, T2-weighted sequence 1 week after surgery. The tethered cord that had been pressed to the ventral side was shifted dorsally (arrow). (Right) Sagittal plane, T2-weighted sequence 1 year after surgery. Hematoma disappeared as compared with the image taken 1 week after surgery. The tethered cord and lipoma have shifted further to the dorsal side.

the dermatome. The patient's gastrocnemius and flexor hallucis longus muscles exhibited slight weakness. The results of the straight-leg-raising test were negative for both legs. She had a typical deformity in her foot—a crooked toe. The patient often had a desire to urinate, but experienced weakness in urination power. She had previously undergone treatment with nonsteroidal anti-inflammatory drugs and urologic medications, but these had not been effective. Magnetic resonance imaging (MRI) revealed a tethered cord and lipomyelomeningocele (Fig. 1, Left). The lipoma occupied the spinal canal space at the level of the L4 vertebra and below. Computed tomography revealed aplasia of the sacral lamina.

Instead of detethering, we performed surgery to reduce the caudal traction force of the tethered cord by opening the lamina and dural sac and shifting the tethered cord to the dorsal side by harnessing the lumbar lordosis. A dorsal incision was made over the lumbar and sacral spine from L3 to S2 vertebrae, and the lamina and lipoma were exposed by retracting the back muscle. The L3, L4, and L5 laminae were resected to observe the dural sac. The margin of the dural sac where the lipoma protruded was confirmed (Fig. 2, Left). The dural sac was cut longitudinally from the height of the L3–L4 disc to the margin of the protruding lipoma. The remaining lipoma that was compressed within the dural

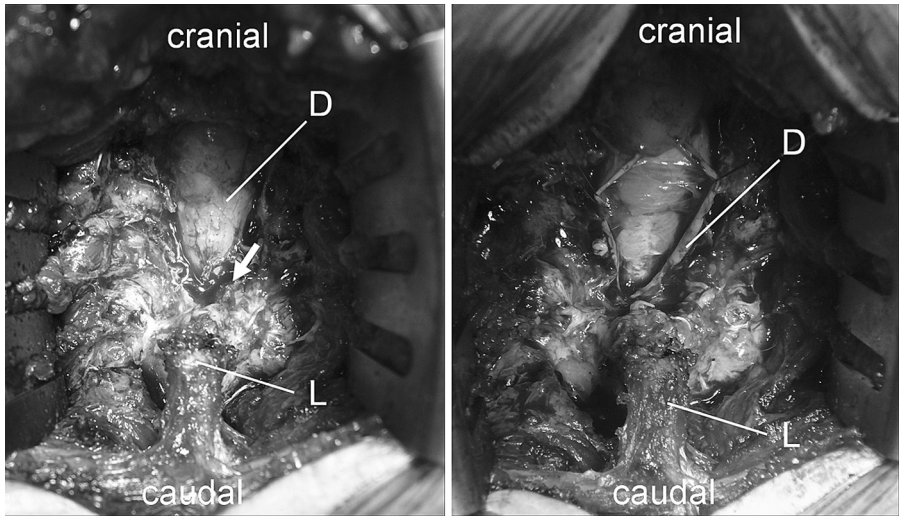

Fig. 2. Photograph of dural sac and lipoma. (Left) The L3, L4, and L5 laminae were resected. The margin of the dural sac where the lipoma protruded is shown (arrow). (Right) The dural sac was cut longitudinally from the height of the L3–L4 disc to the margin. The remaining lipoma that was compressed within the dural sac extruded because of its internal pressure. D, dural sac; L, lipoma.

sac was extruded by its internal pressure (Fig. 2, Right). The margin of the dural sac and the expanded lipoma were covered with an absorbable polyglycolic acid felt (Neoveil; Gunze Limited, Kyoto, Japan) and fibrin glue (Bolheal; Teijin Pharma Limited, Tokyo, Japan). The tethered cord that had been pressed to the ventral side was shifted dorsally as observed in MRI 1 week after surgery (Fig. 1, Middle).

The patient's pain and numbness was alleviated immediately after surgery. Although she experienced an improvement in frequent urination, urodynamic evaluations did not reveal an obvious improvement after surgery. The tethered cord was gradually shifted to the dorsal side, and the caudal traction to the cord appeared to be reduced on MRI performed 1 year after surgery (Fig. 1, Right). The follow-up period was 4 years, and no report of lower limb pain has since been made by the patient.

Discussion

The diagnosis of tethered cord syndrome includes generic description of some forms of anchoring of the distal spinal cord by inelastic structures, such as a myelomeningocele, low-lying conus, or tight filum [2–5]. Abnormal tension on the spinal cord causes neurologic and urologic symptoms. The symptoms of tethered cord syndrome are hypothesized to be caused by a reduction of spinal cord blood flow as a result of increased tension on the spinal cord [9]. It is reasonable to decrease this tension by detethering the spinal cord for the treatment of this pathology.

Tethered cord syndrome was initially considered a pediatric disease. Although the symptoms of tethered cord syndrome appear during the growth period, accompanying an increase in height, some patients experience worsening symptoms in adulthood. The adult-onset form was speculated to be influenced by increased lipoma, accompanied by the increase in weight. The prognosis for adult-onset tethered cord syndrome is poor when treated by conservative methods [10]. Detethering surgery has been reported to improve for adult-onset tethered cord syndrome [11–13]. According to previous reports, back and lower limb pain and muscle weakness in the lower limbs show recovery after detethering surgery. However, urologic dysfunction often persists after this surgery.

In the present case, we performed surgery to reduce the caudal traction force of the tethered cord by opening the lamina and dural sac and shifting the tethered cord and lipoma dorsally by harnessing the lumbar lordosis instead of detethering. The principle of the present method has similarities to laminoplasty for cervical myelopathy caused by spondylosis or ossification of the posterior longitudinal ligament. Laminoplasty is more effective for lordotic alignment cases than for kyphotic cases of myelopathy [14]. Although the main purpose of cervical laminoplasty is decompression of the spinal cord, the tension of the spinal cord influences recovery. The posterior shift of the spinal cord was observed to be insufficient in the kyphotically aligned spine after posterior decompression [14]. Lumbar lordosis increases when symptoms worsen in children with lipomyelomeningocele [6–8]. Because the lumbar spine usually has a lordosis, and the lordosis increases in tethered cord syndrome patients, the tethered cord can be shifted to the dorsal side in most cases and can be a treatment option.

Bowman et al. [1] reported that muscle power in the lower extremities was improved by surgery in 70% of tethered cord syndrome cases. Stavrinou et al. [15] also reported that detethering benefits tethered cord syndrome cases with respect to pain, neurologic function, and urodynamics. However, they concluded that surgical management should be indicated by a thorough multidisciplinary approach and be performed by an experienced neurosurgeon. It is not a simple procedure to detect the anchoring of the distal spinal cord in the dural sac. Haro et al. [16] have recommended intraoperative spinal cord monitoring to avoid injury to fine sacral nerves because functional neural elements are often embedded within the lipomatous tissues. We would, therefore, like to suggest the present method, that is, shifting the tethered cord and lipoma to the dorsal side by harnessing the lumbar lordosis instead of detethering, as a treatment option for tethered cord syndrome.

References

[1] Bowman RM, Mohan A, Ito J, et al. Tethered cord release: a long-term study in 114 patients. J Neurosurg Pediatr 2009;3:181–7.
[2] Bui CJ, Tubbs RS, Oakes WJ. Tethered cord syndrome in children: a review. Neurosurg Focus 2007;23:1–9.
[3] Drake JM. Surgical management of the tethered spinal cord—walking the fine line. Neurosurg Focus 2007;23:1–4.
[4] Lew SM, Kothbauer KF. Tethered cord syndrome: an updated review. Pediatr Neurosurg 2007;43:236–48.
[5] Selden NR. Occult tethered cord syndrome: the case for surgery. J Neurosurg 2006;104:302–4.
[6] Tubbs RS, Bui CJ, Loukas M, et al. The horizontal sacrum as an indicator of the tethered spinal cord in spina bifida aperta and occulta. Neurosurg Focus 2007;23:1–4.
[7] Tubbs RS, Naftel RP, Rice WC, et al. The patient with symptoms following resection of a lipomyelomeningocele: do increases in the lumbosacral angle indicate a tethered spinal cord? J Neurosurg 2006;105:62–4.
[8] Tubbs RS, Wellons JC 3rd, Bartolucci AA, et al. Horizontal sacrum as an indicator of a tethered spinal cord. Pediatr Neurosurg 2002;36:209–13.
[9] Yamada S, Zinke DE, Sanders D. Pathophysiology of "tethered cord syndrome". J Neurosurg 1981;54:494–503.
[10] Phuong LK, Schoeberl KA, Raffel C. Natural history of tethered cord in patients with meningocoele. Neurosurgery 2002;50:989–95.
[11] Huttmann S, Krauss J, Collmann H, et al. Surgical management of tethered spinal cord in adults: report of 54 cases. J Neurosurg 2001;95:173–8.
[12] Pang D, Wilberger JE Jr. Tethered cord syndrome in adults. J Neurosurg 1982;57:32–47.
[13] Yamada S, Lonser RR. Adult tethered cord syndrome. J Spinal Disord 2000;13:319–23.
[14] Fujiyoshi T, Yamazaki M, Kawabe J, et al. A new concept for making decisions regarding the surgical approach for cervical ossification of the posterior longitudinal ligament: the K-line. Spine 2008;33:990–3.
[15] Stavrinou P, Kunz M, Lehner M, et al. Children with tethered cord syndrome of different etiology benefit from microsurgery-a single institution experience. Childs Nerv Syst 2011;27:803–10.
[16] Haro H, Komori H, Okawa A, et al. Long-termoutcomes of surgical treatment for tethered cord syndrome. J Spinal Disord Tech 2004;17:16–20.