J Plast Surg Hand Surg, 2012; 46: 32–36

informa
healthcare

ORIGINAL ARTICLE

Reconstruction of soft tissue defects in the extremities with a pedicled perforator flap: Series of 25 patients

MUSA A. MATEEV[1] & HANNU O.M. KUOKKANEN[2]

[1]*Department of Plastic, Reconstructive Microsurgery, and Hand Surgery, National Hospital of Kyrgyzstan, Bishkek, Kyrgyzstan,* [2]*Department of Plastic Surgery, Tampere University Hospital, Tampere, Finland*

Abstract

Since the introduction of perforator-based flaps, new flaps have been described for reconstruction of soft tissue defects in the extremities. Pedicled perforator flaps, often called propeller flaps, are based on a single perforator and are local axial flaps that can be rotated up to 180^0 with the single perforator as the pivotal point. Pedicle perforator flaps have gained popularity because they have a shorter operating time than free flaps. However, some concern has been raised about their reliability. Here we report our results of 11 soft tissue reconstructions in the lower leg and 14 in the upper extremity. The defects were mostly traumatic or caused by release of burn scars. The mean size of the flaps in the lower leg was 52 cm^2 (range 126–15 cm^2). In the upper extremity it was 24 cm^2 (range 12–35 cm^2). All patients were followed until the wound had healed. In the upper extremity there was only one partial necrosis of the flap, and one patient had an infected wound. One haematoma was evacuated postoperatively, and all the rest healed uneventfully. In the lower leg we had one total necrosis and one partial necrosis of the flap and one infected wound. A free scapular flap was used for salvage in one case, and revision and skin grafting in two. The pedicled perforator flap is reliable, particularly in the upper extremity. The operation is quick and can be done under regional anaesthesia. The flap is thin and has a local texture that gives a good functional and aesthetic result. The pedicled perforator flap is a little unpredictable in the lower leg, probably because the directions of the vessels that arise from the perforator are not consistent.

Key Words: *Propeller flap, pedicle perforator flap, extremity reconstruction*

Introduction

The popularity of perforator free flaps has also meant that pedicled perforator flaps are a choice for reconstruction of soft tissue [1,2]. Asko-Seljavaara introduced the idea of a free style free flap based on any perforator in the body (Paper presented at the Seventh Congress of the International Society of Microsurgery, New York, 1983). The term propeller flap was first described by Hyakusoku et al. in 1991 [3]. We have used a modified radial artery perforator flap since 2003 [4]. In that modification two to three perforator based flaps are developed from a single radial artery. We call this method a propeller flap in flap. Because of good results with this method, it was natural for us to continue to use pedicled perforator flaps in the reconstruction of soft tissues whenever indicated.

In this paper we report our experience with 25 reconstructions with pedicled perforator flaps in the extremities.

Patients and methods

Between 2006 and 2009 a total of 14 defects in the upper extremities and 11 in the lower extremities were covered with pedicled perforator flaps in the National Hospital of Kyrgyzstan. The mean age of the patients who had reconstructions of the upper extremity was 31 years (range 8–57) and in the lower extremity 37 years (range 18–61). The cause of the defects

Correspondence: Hannu Kuokkanen, MD, PhD, Department of Plastic Surgery, Tampere University Hospital, Box 2000, FI-33521 Tampere, Finland. E-mail: hannu.kuokkanen@pshp.fi

(Accepted 15 April 2011)

ISSN 2000-656X print/ISSN 2000-6764 online © 2012 Informa Healthcare
DOI: 10.3109/2000656X.2011.634562

was usually release of burn scars or trauma (Tables I, II). Two of the patients with lower leg defects had diabetes and five of the patients were smokers (Tables I, II).

The source vessels of the perforator used in the upper extremity were the ulnar artery ($n = 5$), radial artery ($n = 4$), dorsal carpal artery ($n = 2$), and dorsal metacarpal artery ($n = 2$). In one case we used the superior ulnar collateral artery perforator flap (Table III). The perforators used in the lower leg usually originated from the posterior tibial and fibular vessels. However, in two cases we used the lateral malleolar artery and in one case dorsalis pedis perforators (Table IV).

The mean size of the flaps in the upper extremity was 24 cm^2 (range 12–35) and in the lower leg 52 cm^2 (range 15–126) (Tables III, IV).

Seven operations were done under general anaesthesia and 18 patients had a brachial plexus block or epidural anaesthesia (Tables III, IV). A tourniquet was used in every case. The mean duration of operation was 90 minutes (range 40–150). The donor site was closed directly in all cases in both extremities.

Results

All patients were followed up to the time of final healing. In the upper extremity there was one partial necrosis of a flap, possibly caused by extensive tension. Revision and skin grafting were followed by good healing. One other patient had a wound infection that was revised and resutured and the wound healed well. One haematoma was evacuated postoperatively and this flap also healed. All other flaps in the upper extremity healed uneventfully.

In the lower leg one patient developed total necrosis of the perforator flap as a result of venous stasis. The flap was removed and reconstructed with a free scapular flap. In two cases the flap was revised because of infection and partial necrosis, and finished with a skin graft, after which they healed with no further complications. In eight cases the flaps healed uneventfully in the lower legs.

Case reports

Case 1 (Patient 14, Tables I, III). A 28-year-old man had a bullet injury to his right arm (Figure 1*a*). The soft tissue injury was revised twice before reconstruction. The patient had a congenital giant naevus of the same arm. The perforators were located by Doppler, and the reconstruction made with a superior ulnar artery perforator flap, 13 × 6 cm, which was rotated as a propeller flap 180^0 (Figure 1*b*, *c*). The donor site was closed primarily (Figure 1*d*). After three weeks the wound had healed and the function was good (Figure 1*e*).

Case 2 (Patient 4, Tables II, IV). A 54-year-old diabetic woman had a bimalleolar fracture of her left leg. Two weeks after the osteosynthesis a soft tissue defect developed on the lateral side of the ankle (Figure 2*a*). After debridement a fibular artery perforator flap 12 × 4 cm was raised, and rotated 180^0 to cover the soft tissue defect (Figure 2*b*, *c*). The donor site was closed primarily (Figure 2*d*). The result was good four months after the reconstruction (Figure 2*e*).

Table I. Data of patients with reconstructions of the upper limb.

Case No.	Age (years)	Sex	Site	Coexistent conditions
1 Burn	21	M	HPS	No
2 Burn	36	M	FDP	Smoker
3 Burn	8	F	HPS	No
4 Traumatic STD	28	M	FDP	Smoker
5 Resection of melanoma	57	F	HDS	No
6 Traumatic STD	19	M	FDP	No
7 Burn SDT (electrical burn accident)	23	M	FDP	Smoker
8 Resection of haemangioma	64	M	HDS	No
9 Traumatic STD	17	M	FDP	No
10 Traumatic STD	33	M	HDS	No
11 Burn	20	M	HDS	No
12 Burn	15	F	FDP	No
13 Traumatic STD	27	M	HPS	No
14 Traumatic STD	28	M	ADP	No

HPS = hand palmar surface, FDP = forearm distal part, HDS = hand dorsal surface, ADP = arm distal part, STD = soft tissue defect.

Table II. Data of patients with reconstructions of the lower limb.

Case No.	Age (years)	Sex	Site	Coexistent conditions
1 Traumatic STD	34	M	Leg DP MS	Smoker
2 Traumatic STD	42	M	Leg DP PS	No
3 Burn scar	21	M	Leg DP MS	No
4 Infected STD after application of plate	54	F	Leg DP LS	Diabetic
5 Resection of carcinoma	61	F	Leg PP MS	No
6 Infected STD after repair of Achilles tendon	23	M	Leg DP PS	No
7 Burn scar	18	M	Foot Plantar Surface	No
8 Resection of tumour	57	F	Leg DP LS	Diabetic
9 Traumatic STD	41	M	Leg DP MS	Smoker
10 Burn scar	20	M	Leg DP AS	No
11 Traumatic STD	37	M	Leg DP LS	No

STD = soft tissue defect, DP = distal part, PP = proximal part, MS = medial surface, LS = lateral surface, PS = posterior surface, AS = anterior surface.

Discussion

The pedicled perforator flaps have several advantages over those of distant free flaps. The texture and colour of the flap are suitable for the defect because of the proximity of the donor area. Pedicled perforator flaps are thin, which is not always the case with free flaps. This is particularly important when treating defects in the distal lower leg, forearm, and hand. The donor site can usually be closed directly, which gives an acceptable donor site scar [1]. If a skin graft has to be used for closure of the donor site the scar will be extensive.

The time needed for the operation is remarkably shorter than that of a free flap. A pedicled perforator flap is a one-team operation and can usually be done under regional anaesthesia. That is why these operations can be done with smaller resources and for medically more compromised patients than free flap surgery.

We used a hand-held Doppler device to localise the available perforators [5], and we feel comfortable with this method. However, with more sophisticated methods like Doppler flowmetry, magnetic resonance imaging (MRI), or computed tomogram (CT), the perforators can be traced with greater accuracy [6–8].

Table III. Reconstructions of the upper limb.

Case No.	Flap	Size (cm)	Duration of operation (hours)	Anaesthetic	Complications
1	RA PF	6 × 3	2	BP	No
2	DCA PF	5 × 4	2	BP	Partial necrosis
3	UA PF	6 × 4	2,5	GN	No
4	UA PF	5 × 7	2	BP	No
5	DCA PF	5 × 4	1,5	BP	No
6	RA PF	8 × 3	2	BP	Haematoma
7	RA PF	7 × 5	2,5	GN	No
8	DCA PF	7 × 4	2	GN	No
9	UA PF	8 × 4	2	BP	Infected
10	DMCA PF	4 × 3	1	BP	No
11	DMCA PF	6 × 4	2	BP	No
12	UAPF	5 × 4	2	BP	No
13	RAPF	7 × 4	2,5	BP	No
14	SUCAPF	13 × 6	1,5	BP	No

RA = radial artery, UA = ulnar artery, DCA = dorsal carpal artery, DMCA = dorsal metacarpal artery, BP = brachial plexus block, GN = general anaesthesia, SUCAPF = superior ulnar collateral artery perforator flap.

Table IV. Reconstructions of the lower limb.

Case No.	Flap	Size (cm)	Duration of operation (hours)	Anst	Complications
1	TPA PF	21 × 6	2	ED	No
2	PA PF	12 × 4	2	ED	No
3	TPA PF	15 × 5	1.5	ED	No
4	PA PF	12 × 4	2	GN	No
5	TA PF	10 × 4	2	GN	Infected
6	LMA PF	9 × 4	1.5	ED	No
7	DPA PF	8 × 3	2	GN	Partial necrosis, distal part
8	LMA PF	5 × 3	1	GN	No
9	TPA PF	19 × 5	2	ED	Necrosis
10	PA PF	12 × 4	2.5	ED	No
11	PA PF	11 × 4	2	ED	No

TPA PF = tibialis posterior artery perforator flap, PA = peroneal artery perforator flap, LMA = lateral malleolar artery, DPA = dorsalis pedis artery, DO = duration of operation, Anst = anaesthetic, ED = epidural, GN = general.

With MRI one could probably follow the axis of the perforator and plan the flap more precisely. In the lower extremity particularly the predictability of the flap would probably be more accurate with better knowledge of the direction of the individual subdermal vessels. The "angiosome" concept introduced by Taylor and Palmer gives guidelines about how to estimate the area vascularised by a single perforator

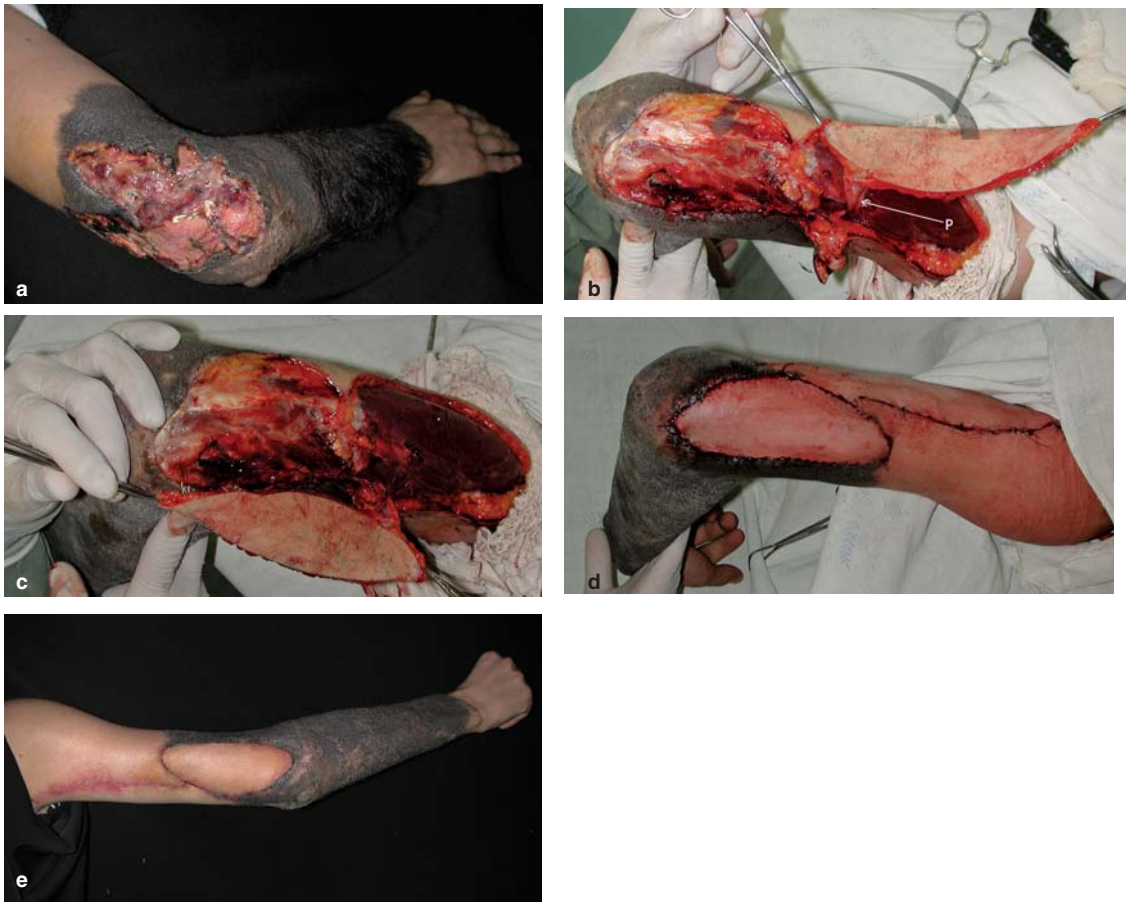

Figure 1. (*a*) A 28-year-old man with a bullet injury to the arm. The patient had a congenital giant naevus in the arm. (*b*, *c*) It was reconstructed with a propeller flap based on the superior ulnar collateral artery. (*d*) The donor site was closed primarily. (*e*) After three weeks the wound had healed.

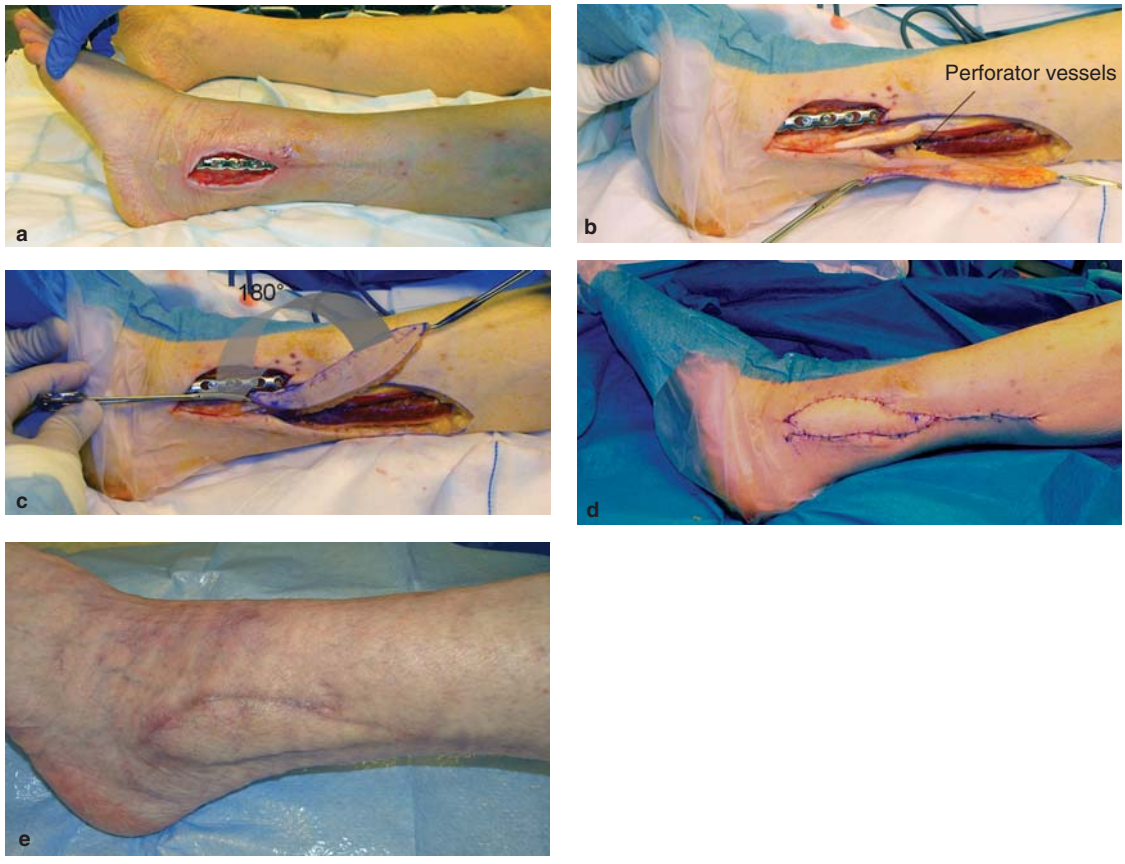

Figure 2. (*a*) A 54-year-old diabetic woman two weeks after operative treatment of a bimalleolar fracture. (*b*) After debridement a fibular artery propeller flap was raised. (*c*) The flap was turned around to cover the defect. (*d*) The donor site was closed primarily. (*e*) The result four months after the reconstruction.

[9]. However, we think that a more specific method to predict the vascularity of the distal edge of the flap, particularly in the lower extremity, would be beneficial in avoiding necrosis of the edge of a large flap.

The perforating vessels are small and have a tendency to kink, which is why they should be handled with great sensitivity. We think that it is useful to save some soft tissue around the perforators, and we do not separate the artery and vein from each other.

Declaration of interest: The authors report no conflicts of interest. The authors alone are responsible for the content and writing of the paper.

References

[1] Pignatti M, Pasqualini M, Governa M, Bruti M, Rigotti G. Propeller flaps for leg reconstruction. J Plast Reconstr Aesthet Surg 2008;61:777–83.

[2] Kroll SS, Rosenfield L. Perforator-based flaps for low posterior midline defects. Plast Reconstr Surg 1988;81:561–6.

[3] Hyakusoku H, Yamamoto T, Fumiiri M. The propeller flap method. Br J Plast Surg 1991;44:53–4.

[4] Mateev MA, Ogawa R, Trunov L, Moldobaeva N, Hyakusoku H. Shape-modified radial artery perforator flap method: analysis of 112 cases. Plast Reconstr Surg 2009;123: 1533–43.

[5] Yu P, Youssef A. Efficacy of the handheld Doppler in preoperative identification of the cutaneous perforators in the anterolateral thigh flap. Plast Reconstr Surg 2006;118:928–33.

[6] Masia J, Kosutic D, Cervelli D, Clavero JA, Monill JM, Pons G. In search of the ideal method in perforator mapping: noncontrast magnetic resonance imaging. J Reconstr Microsurg 2010;26:29–35.

[7] Blondeel PN, Beyens G, Verhaeghe R, et al. Doppler flowmetry in the planning of perforator flaps. Br J Plast Surg 1998; 51:202–9.

[8] Alonso-Burgos A, Garcia-Tutor E, Bastarrika G, Cano D, Martinez-Cuesta A, Pina LJ. Preoperative planning of deep inferior epigastric artery perforator flap reconstruction with multislice-CT angiography: imaging findings and initial experience. J Plast Reconstr Aesthet Surg 2006; 59:585–93.

[9] Taylor GI, Palmer JH. The vascular territories (angiosomes) of the body: experimental study and clinical applications. Br J Plast Surg 1987;40:113–41.

Copyright of Journal of Plastic Surgery & Hand Surgery is the property of Taylor & Francis Ltd and its content may not be copied or emailed to multiple sites or posted to a listserv without the copyright holder's express written permission. However, users may print, download, or email articles for individual use.